

## Two case reports of parapharyngeal lymph node metastasis of thyroid cancer

Guiming Fu<sup>1</sup>, Zhaohui Wang<sup>2</sup>, Jin Chen<sup>2</sup>, Yibo Chen<sup>2</sup>, Chunhua Li<sup>2</sup>

<sup>1</sup>Guangxi Medical University Graduate School, Nanning, 530000, China

<sup>2</sup>Department of Head and Neck Surgery, Sichuan Cancer Hospital, University of Electronic Science and Technology, Chengdu, 610000, China

**Abstract:** The regional lymph node metastasis rate of thyroid cancer has been reported to be approximately 12.60%; parapharyngeal space (PPS) lymph node metastasis is even more rare and usually occurs as a result of postoperative recurrence and metastasis. In this paper, we describe two highly challenging cases of thyroid cancer with lymph node metastasis to the PPS that were surgically resected from 2015-2017. Two cases of thyroid cancer were successfully treated by surgery using the traditional transcervical approach. Neither patient had severe postoperative complications. To date, the patients have not experienced recurrence or other metastasis (19 months for one patient and half a year for the other patient). Parapharyngeal lymph node metastasis of thyroid cancer is rare and usually occurs as a result of postoperative recurrence and metastasis. Complete surgical resection and radioactive iodine treatment (RAI) are the primary methods used to treat the disease. Preoperative computed tomography and magnetic resonance imaging (CT/MRI) examination to select an appropriate surgical approach is crucial to a successful operation.

**Keywords:** Thyroid cancer; Parapharyngeal space transfer; Parapharyngeal neoplasm

Received 2 July 2017, Revised 25 September 2017, Accepted 27 September 2017

\*Corresponding Author: Zhaohui Wang, wangzh912@163.com

### 1. Introduction

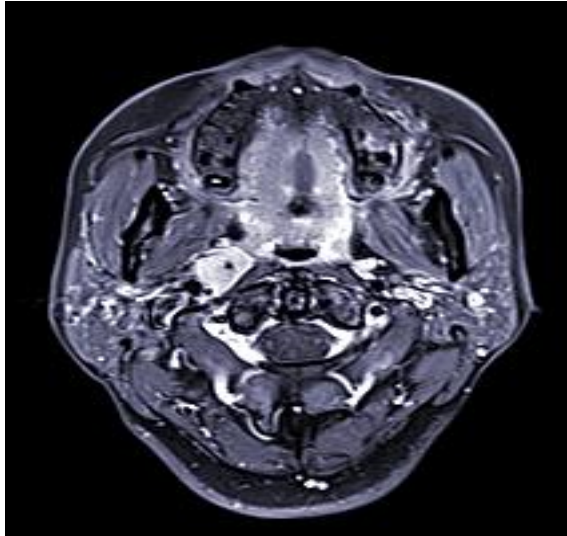
In general, thyroid cancer often metastasizes to the level II-VI cervical lymph nodes. The regional lymph node metastasis rate of thyroid cancer has been reported to be approximately 12.60% (83/657)[1]; parapharyngeal space (PPS) lymph node metastasis is even more rare, with an incidence ranging from 0.43% (3/696) to 10.42% (5/48)[3,4]. It usually occurs as a result of postoperative recurrence and metastasis[2], and a recent study reported that the incidence rate of this disease increased to about 90.90% (20/22)[5]. Complete surgical resection and radioactive iodine treatment (RAI) are the major methods used to treat the disease and are mostly accompanied by a substantial level of risk. In our paper, two challenging cases of thyroid cancer with lymph node metastasis in the PPS are reported; the diagnosis and treatment are discussed.

### 2. Materials and Methods

#### 2.1. Case 1

A 43 years old female underwent a hemithyroidectomy of the right lobe and one third of the left lobe with selective right neck dissection (level VI) in 1999. Histopathological analysis demonstrated a pT2N1bM0 papillary thyroid cancer (PTC). In July 2015, the growth of a nodule in the residual left lobe area was found by high frequency ultrasound during the follow-up period. However, no definite positive sign was found during the physical examination. Thyroid hormone test conducted showed levels of T3 level to be 1.18ng/ml, T4 to be 94.52ng/ml, TSH to

be 2.85μU/ml, and TG to be <10.00ng/ml. A preoperative ultrasound examination revealed a 19×14×14mm hypoechoic nodule near the left lower lobe, with well-defined edges and shape and a rich blood signal on July 13, 2015. Then, magnetic resonance imaging (MRI) showed a round 12×15×16mm enhanced nodule near the left lobe that was determined to be a metastasis of a cervical lymph node. Additionally, an 18×14×16mm enlarged lymph node was also found in the right side of the PPS (Figure 1). The result of a fine-needle aspiration biopsy (FNAB) showed that the nodule near the left lobe exhibited slightly increased deep staining of the follicular epithelial cell nuclei, which were disordered. In this case, we eventually decided to resect the residual thyroid, the right neck lymph nodes at levels II-VI and the parapharyngeal suspicious neoplasm. During the operation, the location of the parapharyngeal neoplasm was noted to be deeper than that determined in the preoperative assessment, and the neoplasm could not be palpated. To completely expose the neoplasm, we removed the right posterior belly of the digastric muscle and resected the end of the muscle. Postoperative pathology confirmed that the neoplasms of the neck lymph nodes near level VI and the right PPS were the result of metastasis of medullary thyroid cancer (MTC) (Figure 2); the mass in the left lobe was a nodular goiter. The patient has survived without recurrence or other metastasis for 24 months.



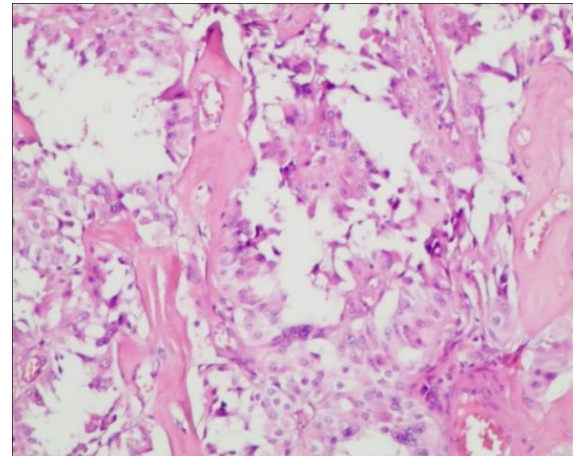
**Figure 1.** An 18×14×16mm enhanced lymph node in right side of the PPS, with clear boundaries and rules, and there was significant tissue necrosis in middle area.

## 2.2. Case 2

A 28-year-old female had a thyroid nodule with a 2-month history. The nodule located in the left lobe was 30×20×20mm and was hard and well-defined without tenderness. Additionally, multiple enlarged lymph nodes were present in levels III-IV of the left neck that exhibited partial fusion conglomeration; the largest node was 35×20×25mm, had no clear boundary or regular shape and exhibited calcifications. Many enlarged lymph nodes were found in levels III, IV, and VI in the left neck; the largest lymph node was 31×20×22mm. A preoperative MRI scan showed that the left lobe nodule was approximately 28×28×23mm and was obviously enhanced. Enlarged lymph nodes were also found in the left neck and left side of the PPS with sizes of 30×19×24mm and 30×30×25mm (Figure 3), respectively. The FNAB demonstrated that the left lobe nodule was PTC, and tumor cells were also found in the left neck lymph nodes (level IV). Finally, we decided to perform total thyroidectomy and the removal of bilateral lymph nodes at level VI, the left neck lymph nodes at levels II-V and the suspicious neoplasm in the left PPS.

Because the neoplasm in the left PPS was larger than that of Case 1, we resected the left submandibular gland to remove the parapharyngeal lymph node metastasis. Postoperative pathology of this case showed that the left lobe nodule was PTC. Additionally, the right lobe exhibited an unexpected finding of a 4.0mm diameter focal PTC. One lymph node metastasis was found in the left PPS (Figure 4), and eight lymph nodes had metastasized to the left neck. Two months later, the patient underwent RAI. The patient is currently receiving TSH suppression

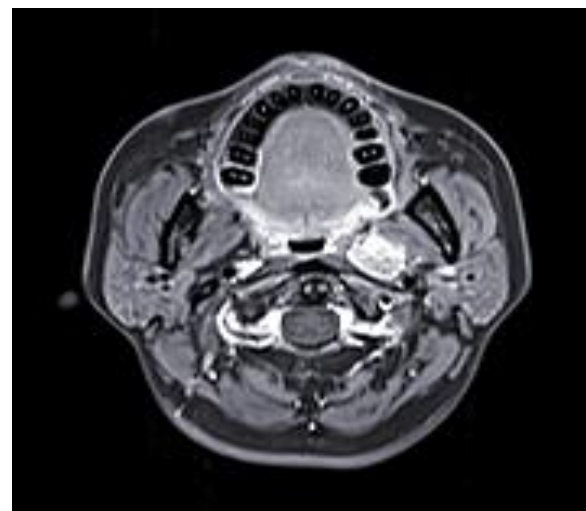
therapy and has survived without recurrence for 10 months.



**Figure 2.** Lymph node metastasis of thyroid medullary carcinoma in right of PPS.

## 3. Results

Two cases of thyroid cancer were successfully treated by surgery, and no severe complications occurred postoperatively. The two patients are currently receiving TSH suppression therapy and follow-up examinations. The patients have survived without recurrence or other metastasis for 24 months and 10 months.



**Figure 3.** The enlarged lymph node in the left of PPS was around 30×30×25 mm, pushing the left oropharyngeal wall.

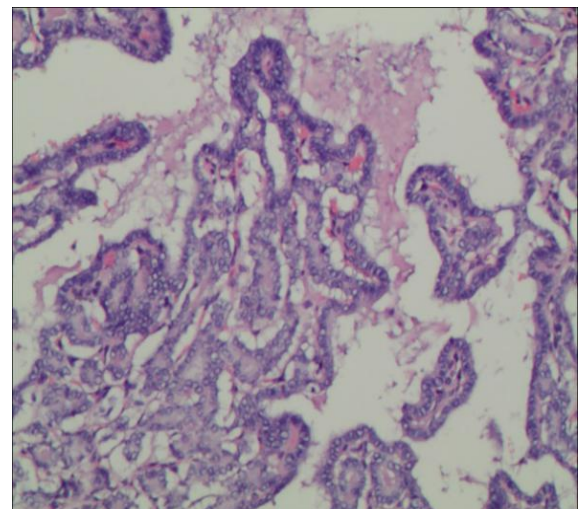
## 4. Discussion

The PPS extends lateral and anterior to the lateral retropharyngeal space and separates this area from the masticator and the parotid space, which contains fat, the internal maxillary, the ascending pharyngeal

arteries and the pharyngeal venous plexus. The thyroid cancer metastasis to the PPS is hypothesized to occur via two pathways: the internal jugular vein lymph chain and the direct drainage of thyroid lymph. In general, the PPS can harbor many types of neoplastic lesions, such as primary tumors, lymph node metastases, and lymphoma. Transformation of tumors in the nasopharyngeal area, breast, and esophageal area as well as malignant paraganglioma and lymphomatosis must be excluded. Additionally, oropharyngeal neoplasms, which are often located deep in the digastric area or inside of the internal carotid artery and internal jugular vein, are difficult to locate by ultrasound and analyze by cytological biopsy. Computed tomography (CT) and MRI scans can accurately show the sizes, numbers and positions of parapharyngeal neoplasms and are regarded as good diagnostic methods. Additionally, computed tomography angiography (CTA) and magnetic resonance imaging angiography (MRA) have a unique advantage in determining the relationship between metastases and cervical vessels. The identification of paraganglioma is easier using CTA and MRA than with other traditional methods. Metastasized lymph nodes in the PPS often appear as singular and exhibit a clear boundary, heterogeneous density, liquefaction necrosis and calcifications on contrast-enhanced CT. Compared to the appearance of parapharyngeal neoplasms and normal tissue on contrast-enhanced CT, the signals on MRI are even more obvious. Recently, Turner F et al. noted that the sensitivity of 18F-FDG position emission tomography (PET) and RAI scanning were better than that of CT or MRI[6]. We hope that more analysis can be completed in this area in the future. Due to the limited anatomical space in the PPS, choosing an appropriate surgical approach is critical for a successful operation and the preservation of the anatomical organization. Neoplasms of the mandible, submandibular gland and digastric and parapharyngeal regions are difficult to expose during surgery. We believe that by taking advantage of the space between the tumor and the surrounding tissue (internal carotid artery, cranial nerve, etc.) during surgery, the tumor can be resected without residual lesions. Several surgical approaches have been reported in publications including the submaxillary interspace approach, the parotid gland approach, and the oral approach. In some cases, mandibular truncation may be required. The two cases we described here were performed by resecting the digastric muscle or removing the ipsilateral submandibular gland through a surgical incision in the lateral neck. No severe complications occurred after surgery.

In the preoperative examination, an understanding of the relationship between parapharyngeal neoplasms and the surrounding tissue should be

established using CT or MRI images to prepare for the incision of the mandible. The most common complication is unpredicted delayed bleeding. Due to the rich blood supply and the deep location of the tumor, care must be taken during the operation. Second, the operation must be conducted by an experienced surgeon. Many important structures (glossopharyngeal nerve, sympathetic nerve, accessory nerve, internal carotid artery, etc.) may be accidentally injured; these injuries could lead to serious consequences. These structures must be identified and protected as much possible. Third, postoperative cerebrospinal fluid leak and meningitis may occur in some cases, which may be caused by damage to soft tissue in the jugular foramen region and by surgical infection. Filling the defect with surrounding fat has been shown to solve this problem. If damage or infection occurs, it is necessary to monitor the intracranial pressure and administer antibiotics. In October 2015, Giordano L[7] hypothesized that a video-assisted minimally invasive transcervical approach can identify the critical surgical landmarks and decrease the rate of complications in the case of lymph node metastasis of the PPS.



**Figure 4. The thyroid papillary carcinoma lymph node metastases to the left PPS.**

Currently, no one unified conclusion has been globally accepted regarding the classification of local or distant lymphatic metastasis to the PPS. Surgery and RAI are still regarded as the primary treatment methods for this disease. Using surgery and RAI, Xiang Jun et al. reported total 5 year survival and a recurrence free survival rates of 77.7% and 55.5%, respectively[8]. However, relative data regarding the effect of RAI on parapharyngeal lymph node metastasis of thyroid cancer is lacking. RAI has little efficacy on MTC and poorly differentiated or anaplastic thyroid cancer.

## 5. Conclusion

Lymphatic metastasis of thyroid cancer to the PPS rarely occurs. High frequency ultrasound and FNAB may play a limited role in the preoperative diagnosis. For these cases, CT/MRI scans may be the best choice for distinguishing the tumor from other tissues. Completely exposing the tumor in the PPS according to CT/MRI images is crucial for a successful operation. Surgery combined with RAI can frequently have a substantial effect on PTC. However, the effect of RAI is uncertain for other pathological types of thyroid cancer.

## Conflict of Interest

No conflict of interest was declared by the authors.

## Financial Disclosure

The authors declared that this study has received no financial support.

## References

- [1] Xue MY, Wang MM, Li FY, et al. Differentiated thyroid cancer rare transfer case analysis and literature review[J]. China and oncology China's oncologist education, 2014, 2(1):14-19.
- [2] Kainuma K, Kitoh R, Yoshimura H, et al. The first report of bilateral retropharyngeal lymph node metastasis from papillary thyroid carcinoma and review of the literature[J]. Acta. Otolaryngol, 2011, 131(1):1341-1348.
- [3] Desuter G, Lonneux M, Plouin-Gaudon I, et al. Parapharyngeal metastases from thyroid cancer[J]. Eur. J. Surg. Oncol., 2004, 30(1):80-84.
- [4] Yuce I, Cagli S, Bayram A, et al. Regional metastatic pattern of papillary thyroid carcinoma[J]. Eur. Arch. Otorhinolaryngol., 2010, 267:437-441.
- [5] Moritani S. Parapharyngeal metastasis of papillary thyroid carcinoma[J]. World. J. Surg., 2016, 40(1):350-355.
- [6] Turner F, Paris J, Giovanni A, et al. Papillary thyroid carcinoma metastasis to parapharyngeal lymph nodes: interest of the PET scan[J]. Rev. Laryngol. Otol. Rhinol(Bord), 2006, 127(2):175-178.
- [7] Giordano L, Pilolli F, Toma S, et al. Parapharyngeal metastases from thyroid cancer: surgical management of two cases with minimally-invasive video-assisted technique[J]. Acta. Otorhinolaryngol. Ital., 2015, 35(1):289-292.
- [8] Xiang J, Shen Q. Surgical treatment of parapharyngeal lymph node metastasis arising from papillary thyroid carcinoma: A report of 13 patients[J]. Chin. J. Pract. Surg., 2014, 736(2):978-980.